

## Carta al Director

Mercedes Chanzá<sup>1</sup>  
Sonia Vidal<sup>1</sup>  
Concepción Gimeno<sup>1,2</sup>

### *Rhizobium radiobacter* in pulmonary abscess associated with postgripal necrotizing pneumonia

<sup>1</sup>Consortio Hospital General Universitario de Valencia

<sup>2</sup>Facultad de Medicina. Departamento de Microbiología. Universidad de Valencia

Sir,

A 64-year-old male who attended emergency department with acute respiratory failure and dyspnoea with a fever of 38.5 °C. Personal history: active smoker, Korsakoff syndrome, alcoholic polyneuropathy, chronic anaemia, chronic liver disease. During auscultation presents vesicular murmur decreased in both hemithorax with crackling sounds with left predominance.

Blood analysis summary: leukocytosis with 20,400 cells/mm<sup>3</sup> (94% of which were polymorphonuclear lymphocytes), anaemia (haemoglobin = 11 g/dL) and alteration of hepatic enzymes due to chronic liver disease. Arterial blood gases: 76 mmHg O<sub>2</sub> saturation. The chest x-ray shows condensation in the left upper lobe with aerial bronchogram. Microbiology: negative blood cultures. Tested positive for RNA of Influenza A virus by molecular techniques. Initial sputum sample was of a poor quality, throughout his period of hospitalization a further sample was sought.

The patient on arrival had an antibiotic treatment with amoxicillin/clavulanic acid which was replaced by Oseltamivir and levofloxacin, initiating high flow continuous positive airway pressure (CPAP). Fluid therapy and bronchodilators were added. The patient improves in the next few days becoming afebrile.

The seventh day a significant deterioration is detected. A new blood test was made, in which a leukemic reaction was observed. A new chest x-ray was also requested, informing the radiologist of a cavity with hydro-aerial levels in a condensation of the left upper lobe, compatible with abscessification. In addition, it was observed affected parenchyma with alveoli-interstitial pattern (figure 1). A computerized axial tomography (CT) of the chest with contrast was processed, observing a cavitated voluminous mass/condensation. Reports of crops of a second sample of sputum as well as that of a broncho-

alveolar lavage arrived from microbiology, with the result of "abundant and pure culture of *Rhizobium radiobacter*".

This organism was initially identified by mass spectrometry MALDI-TOF<sup>®</sup>, its biochemical profile obtained by the Beckman Coulter<sup>®</sup> Microscan autoanalyzer and was subsequently confirmed by genomic amplification (PCR) and sequencing of the 16S rDNA coding for the 16S rRNA gene.

A study of antimicrobial agents sensitivity using the microdilution system incorporated to identification/susceptibility of non-fermenting gram-negative of Microscan panels, was made, taking into account the breakpoints in the Clinical and Laboratory Standards Institute (CLSI). Studied strain was sensitive to most of the antibiotics tested as: cefotaxime, cefepime and piperacillin/tazobactam, gentamicin, ciprofloxacin and cotrimoxazole. Taking into account the antibiogram report, the treatment was modified to piperacillin/tazobactam. The evolution was satisfactory, improving respiratory function and disappearing the lung abscess.

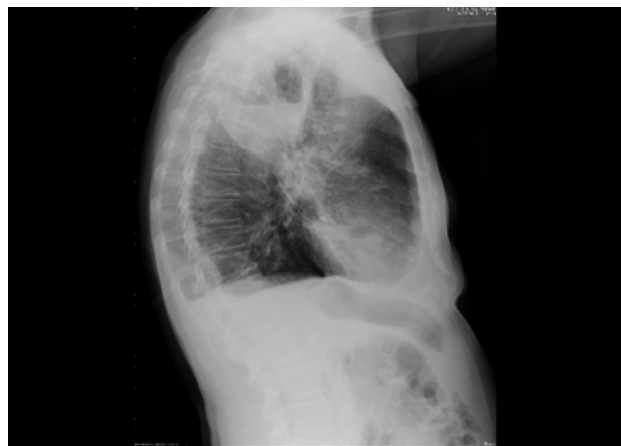
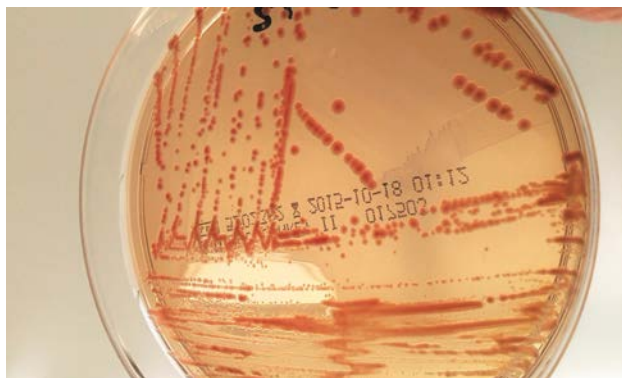

Figure 1 | Pulmonary abscess in the left upper lobe

Correspondence:  
Mercedes Chanzá Aviñó  
Consortio Hospital General Universitario de Valencia  
E-mail: chanza\_mer@gva.es

*R. radiobacter* (formerly *Agrobacterium radiobacter*), is a gram-negative bacillus of rapid growth in common media like MacConkey agar, where they appear as round, bright and orange, non-haemolytic colonies on blood agar, glucose non-fermenter, aerobic, mobile, urease and positive oxidase<sup>1</sup> (figure 2).



**Figure 2** | *Rhizobium radiobacter* culture in MacConkey agar

It is a phytopathogen, not very virulent for humans, being the species *R. radiobacter* and *R. tumefaciens* the ones which occasionally cause infection in humans. *R. radiobacter* is considered as an opportunistic pathogen, which appears to infects preferentially chronically debilitated patients or immunosuppressed carriers of any intravascular catheter<sup>2,3</sup>. *R. radiobacter* is widely distributed in the ground including the hospital environment and can cause nosocomial infections. Few cases of human infections have been published in the literature, most of them associated to bacteraemia and infections resulting from the implementation of intravascular devices<sup>4</sup>, immunosuppression states and hematologic diseases<sup>5</sup>. Isolated cases of endophthalmitis<sup>6</sup>, abdominal infection<sup>7</sup>, endocarditis<sup>8</sup> and septic pulmonary embolism<sup>9</sup> have been described.

This case study reports a rare occurrence of lung abscess caused by *R. radiobacter* during the course of a necrotizing pneumonia, subsequent to Influenza A virus. Our patient was not a carrier of intravascular catheter, designated as one of the most common entrance doors for the source of these infections, but we believe that there are other risk factors that may have contributed to infection such as: weakening caused by chronic anaemia with subsequent leukemoid reaction, and also the situation of special susceptibility caused by previous viral pneumonia, which facilitated the bacterial superinfection<sup>10</sup>.

The *R. radiobacter* identification shows an excellent correlation between mass spectrometry (MALDI-TOF), conventional microbiological methods and genome sequencing.

After bibliographic review, we think that susceptibility study should be always individualized since the behaviour to antimicrobials does not follow a certain pattern and may vary its response to them.

## ACKNOWLEDGEMENTS

Dr. Jose Garcia Moreno, University Hospital Dr. Peset. Valencia

## FUNDING

No funding to declare.

## CONFLICT OF INTEREST

No conflict of interest to declare.

## REFERENCES

- Zhang HP, Fan JM, Huang DH, Zeng YM. Clinical and microbiological characteristics of *Rhizobium radiobacter* infectious: six cases report and literature review. *Zhonghua Jie He He Hu Xi ZaZhi* 2010; 33:93-8.
- Chen CY, Hansen KS, Hansen LK. *Rhizobium radiobacter* as an opportunistic pathogen in central venous catheter-associated bloodstream infection: case report and review. *J Hosp Infect* 2008; 68:203-7.
- Ponnapula S, Swanson JM, Wood GC, Boucher BA, Wells DL, Croce MA et al. Treatment of *Rhizobium radiobacter* bacteremia in a critically ill trauma patient. *Ann Pharmacother* 2013; 47:1584-7
- Sikgoz Tasbakan M, Görümlü G, Pullukcu H, Sanli UA, Sipahi OR, Karabulut B et al. A rare cause of catheter-related bacteremia: *Rhizobium radiobacter*. *Mikrobiyol Bul* 2008; 42: 349-52.
- Karadağ-Öncel E, Ozsüreki Y, Aytacı S, Kara A, Cengiz AB, Ceyhan M. Implantable vascular access port-associated bloodstream infection caused by *Rhizobium radiobacter*: a case report. *Turk J Pediatr* 2013; 55:112-5.
- Al-Abdullah AA, Al-Falah M, Al-Rashaed S, Khandekar R, Arevalo JF. Endophthalmitis caused by *Rhizobium radiobacter* after posterior chamber phakic intraocular lens implantation to correct Myopia. *J Refract Surg* 2015; 31:561-3.
- Badrising S, Bakker L, Lobatto S, Van Es A. *Peritonitis in a peritoneal dialysis patient due to Rhizobium radiobacter and Moraxella osloensis*: case report and literature review. *Perit Dial Int* 2014; 34:813-5.
- Piñerúa-González JF, Zambrano-Infantín R, Calcaño C, Montaña C, Fuenmayor Z, Rodney H et al. Infective endocarditis by *Rhizobium radiobacter*. A case report. *Invest Clin* 2013; 54: 68-73.
- Romano L, Spanu T, Calista F, Zappacosta B, Mignogna S, Sali M et al. *Tsukamurella tyrosinosolvans* and *Rhizobium radiobacter* sepsis presenting with septic pulmonary emboli. *Clin Microbiol Infect* 2011; 17:1049-52.
- Lai CC, Teng LJ, Hsueh PR. Clinical and microbiological characteristics of *Rhizobium radiobacter* infections. *Clin Infect Dis* 2004; 38:149-53.